

Marco Degidi  
Diego Nardi  
Adriano Piattelli

# One abutment at one time: non-removal of an immediate abutment and its effect on bone healing around subcrestal tapered implants

## Authors' affiliations:

Marco Degidi, Diego Nardi, Private Practice, Bologna, Italy  
Adriano Piattelli, Dental School, University of Chieti-Pescara, Chieti, Italy

## Corresponding author:

Prof Adriano Piattelli  
Dental School  
University of Chieti-Pescara Via F. Sciucchi 63  
66100 Chieti  
Italy  
Tel.: +39 0871 355 4083  
Fax: +39 0871 355 4076  
e-mail: apiattelli@unich.it

**Key words:** implantology, osseointegration, stomatology

## Abstract

**Objectives:** The aim of this prospective study was to assess the effects of abutment removal after 6 months on bone healing after the subcrestal placement of immediately restored, tapered implants in cases of partial posterior mandibular edentulism.

**Material and methods:** Each of the 24 patients with partial posterior mandibular edentulism was consecutively treated with two immediately restored 3.5 mm diameter tapered implants. A total of 48 implants were placed in healed sites and immediately splinted with a temporary restoration, which was placed in such a way as to avoid occlusal contact. Twenty-four weeks after surgery, 12 patients underwent the standard prosthetic protocol: the abutments were removed and impressions were made directly on the implant platform. Twelve patients underwent the "one abutment at one time" protocol: impressions were made of the abutments using snap-on abutment copies. The final restoration was delivered approximately 6 months after implant insertion. Vertical and horizontal bone changes were assessed using periapical radiographs immediately after surgery and at 6-, 12-, 24- and 36-month follow-up examinations.

**Results:** All implants osseointegrated and were clinically stable at the 6-month follow-up. No statistically significant difference was evidenced between the two groups regarding the measurement of vertical bone healing. A small but significant horizontal bone loss was evidenced in the hard tissue portion over the implant platform in the period of time between the 6-month and 1-year follow-up in the control group.

**Conclusions:** The non-removal of an abutment placed at the time of surgery results in a statistically significant reduction of the horizontal bone remodeling around the immediately restored, subcrestally placed, tapered implant in cases of partial posterior mandibular edentulism.

The subcrestal placement of the implant shoulder was proposed (Buser et al. 1993) in order to obtain a more comfortable prosthetic emerging profile and improve soft tissue esthetic results. Modifying the sinking depth of the border between the smooth and the rough surfaces of standard two-piece, butt-joint connection implants with a machined collar was supposed to compensate for the loss of vertical bone height evidenced by many studies (Albrektsson et al. 1986; Hartman & Cochran 2004; Roos-Jansaker et al. 2006). However, the subcrestal placement of such a type of implant has recently been associated with an increased marginal bone loss (Stein et al. 2009) and Hämmerle had already concluded that such an approach was not to be recommended (Hämmerle et al. 1996). This increased loss may be caused by the bacterial colonization of the microgap present in the fixture-abutment

junction, as had already been reported by Quirynen (Quirynen & van Steenberghe 1993; Quirynen et al. 1994).

This problem was resolved by the introduction of a subcrestally placed tapered implant with a progressive-thread and a rough collar, and nearly no bone loss was observed in both human and animal subjects (Degidi et al. 2008, 2010; Weng et al. 2008; Romanos et al. 2010). It has been demonstrated by many studies involving two-piece implants that the majority of bone loss occurs in the very first months after surgery. An animal study involving tapered implants (Abrahamsson et al. 2003) reported that the largest bone level alteration occurred during the first 3 months after healing. The implant system used in our study has already proved to be predictable in maintaining peri-implant tissues, mainly thanks to its nearly gap-free and stable

## Date:

Accepted 15 October 2010

## To cite this article:

Degidi M, Nardi D, Piattelli A. One abutment at one time: non-removal of an immediate abutment and its effect on bone healing around subcrestal tapered implants. *Clin. Oral Impl. Res.* 22, 2011; 1303–1307.  
doi: 10.1111/j.1600-0501.2010.02111.x

tapered connection to the abutments. Romanos et al. (2001) reported in an animal study the feasibility of the immediate loading of tapered implants placed in healed sites in the posterior mandible. Following the guidelines of the implant manufacturer, Donovan et al. (2010) recently observed that mineralized hard tissue on the implant shoulder was found in 69% of the implants, and minimal bone loss was reported at the 1-year follow-up visit. In a histological case report (Degidi et al. 2008), the authors observed the presence of newly formed bone 2.0 mm above the level of the immediately loaded implant shoulder after a healing period of only 4 weeks. No resorption of the coronal bone or infrabony pockets were present and dense connective tissue with only a few scattered inflammatory cells was observed at the level of the implant shoulder. In another animal study (Weng et al. 2008), the authors reported that with subcrestally placed implants bone tissue overgrew the microgap and established the first bone-to-implant contact directly on the healing abutment, notwithstanding the fact that the implants were placed using a two-stage approach.

In the prosthetic protocol for this type of implant, standard abutments are removed and impressions are taken using a customized tray with standard long pin components directly on the implant platform. This prosthetic handling can be considered a compromising factor for the stability of the subcrestal biological area. Lazzara & Porter (2006) reported that the removal and reconnection of the abutment created a soft tissue wound with subsequent bone resorption due to the attempt made by the soft tissue to establish a proper biologic dimension of the mucosal barrier attachment to a stable implant surface.

The aim of this prospective study was to assess the effects of abutment removal after 6 months on bone healing after the subcrestal placement of immediately restored, tapered implants in cases of partial posterior mandibular edentulism. Our objective was to see if non-removal of the abutment placed at the time of the surgery would improve bone healing around the implants.

## Material and methods

The present prospective study included patients with partial posterior mandibular edentulism with an age of 18 years or more. The condition of the opposing dentition was not considered to be a discriminating factor. This study was designed and conducted in full accordance with the World Medical Association Declaration of Helsinki, as revised in 2002. All patients signed a specific written informed consent form. Each of them received two 3.5 mm diameter square threaded,

grit-blasted and acid-etched implants with a tapered connection (ANKYLOS<sup>®</sup>, DENTSPLY Friadent, Mannheim, Germany) positioned in a partially edentulous posterior mandible. Patients were not accepted into the study if they met any of the following exclusion criteria: (1) active infection in the sites intended for implant placement; (2) systemic disease that could compromise osseointegration; (3) treatment with radiation therapy in the craniofacial region within the previous 12 months; (4) if they smoked more than 10 cigarettes per day; (5) pregnancy or lactation; (6) bruxism; and (7) unsuitable quantity of bone in the surgery site or need of bone augmentation procedures before implant placement. All implants were placed in healed sites by one experienced surgeon (M. D.) in a private dental office in Bologna, Italy.

During the implant placement procedure, the insertion torque and the implant stability quotient (ISQ) were recorded using a surgical unit (FRIOS Unit E, W&H Dentalwerk GmbH, Buermoos, Austria) and a digital measurement probe (Osstell AB, Gamlestadsvägen 3B, Göteborg, Sweden). Patients were dropped from the study if any of the implants met one of the following exclusion criteria (1) insertion torque < 25 N cm, and (2) an ISQ of < 60.

Preoperative analysis of anatomical features was performed using panoramic radiography. Impressions were made of the maxilla and mandible, and laboratory casts were made. The shade and mold of the prosthetic teeth were selected and appropriate wear-resistant commercial denture teeth (VITA Physiodens, VITA Zahnfabrik, H. Rauter GmbH & Co. KG, Bad Säckingen, Germany) were chosen. Two or three teeth were arranged on a cast mounted on a semi-adjustable articulator and joined with auto-polymerizing acrylic resin to create the temporary restoration.

Anti-microbial prophylaxis was obtained with the use of 500 mg  $\beta$ -lactam antibiotic (Amoxicillin, Pfizer Manufacturing, Puurs, Belgium) twice daily for 5 days, starting 1 h before surgery. Local anesthesia (2% articaine/adrenaline 1:100,000) was administered at the time of surgery. Surgery began with a mid-crestal incision, a full-thickness flap was elevated and the crestal ridge was exposed. Two 9.5 or 11 mm long implants were placed with the rough crestal collar positioned at least 1 mm beneath the bone crest. If both implants fulfilled the inclusion criteria, the abutments (Standard A<sup>®</sup>, DENTSPLY Friadent) were connected to the implants and splinted using the intraoral welding technique (Degidi et al. 2010). The temporary acrylic restoration was then relined in position with a small quantity of auto-polymerizing acrylic resin, the correct vertical dimension and occlusion were checked in order to avoid contacts in centric and lateral excursions. The restoration was removed from the oral cavity,

completely filled with heat-processed acrylic, trimmed, polished and reinserted. The restoration was connected to the abutments by tightening the titanium retaining screws with 20 N cm of torque. Screw holes were closed with light-cured composite resin. The soft tissue was positioned around the abutments and sutured into place. Oral hygiene instructions were provided and patients were instructed to have a soft diet for 8 weeks. Sutures were removed 14 days after surgery. Twenty-four weeks after implant insertion, the provisional restoration was removed, implant mobility was checked and final impressions were taken using polyether impression material (Impregum, 3M-Espe, St. Paul, Minnesota, USA).

Twelve patients were enrolled in the control group and underwent the standard prosthetic protocol. The standard abutments were removed and the impressions were made with a customized tray using standard long pin components directly on the implant platform. Abutments were also removed three more times: at the metal framework and biscuit try-in and at the delivery of the final restoration.

Twelve patients were enrolled in the test group and underwent the "one abutment at one time" protocol. Impressions were made on the abutments using a standard tray and snap-on abutment copies.

The final metal-ceramic restoration was delivered approximately 6 months after implant insertion.

The following observations were made (Fig. 1):

- Restoration success, defined as an absence of fractures in both the acrylic superstructure and the welding joints.
- Implant success, defined as an absence of radiological translucency, implant mobility, swelling or pain in the surgical site at time of follow-up examinations.
- Bone healing in the in the cylindrical area drilled during surgery measured from the implant platform corner defined as:
  - Vertical height of the bone peak;
  - Horizontal growth of the bone over the implant platform;

All the hard tissue measurements were assessed using periapical radiographs taken with a customized positioning jig. Each periapical X-ray was digitized with a scanner (Epson Expression 1680 Pro, Epson Italia, Cinisello Balsamo, Milano, Italy) and analyzed with measurement software (Meazure<sup>®</sup> 2.0 build 158, C Thing Software, Sunnyvale, CA, USA) using platform height and implant length as double cross references (Jaffin et al. 2007).

- Biological or technical complications and any other adverse event (Figs 2–7).

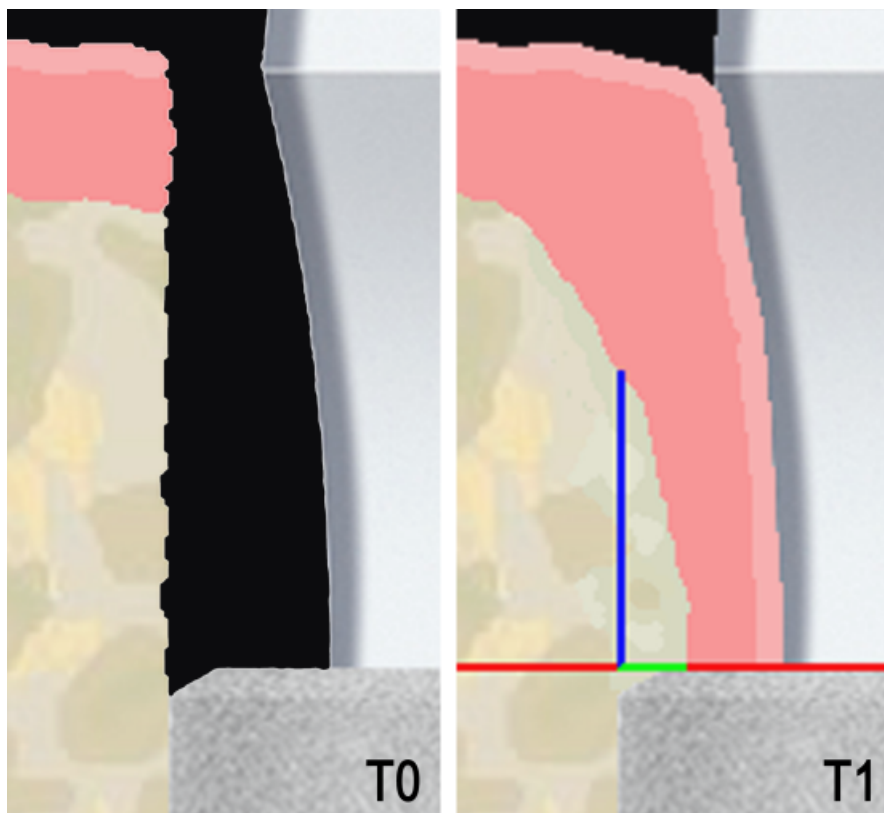


Fig. 1. Vertical height of the bone peak and horizontal growth of the bone over the implant platform were measured from the implant platform corner in the cylindrical area drilled during surgery.

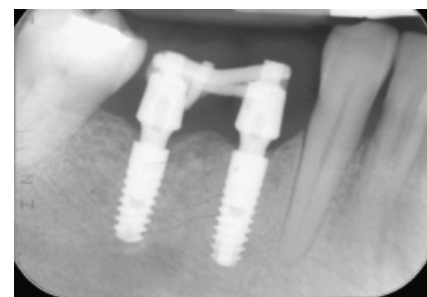


Fig. 4. Test case: periapical radiograph taken 6 months after surgery.

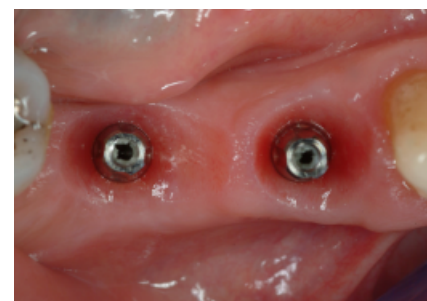


Fig. 5. Test case: healing of the soft tissue 6 months after surgery, occlusal view.

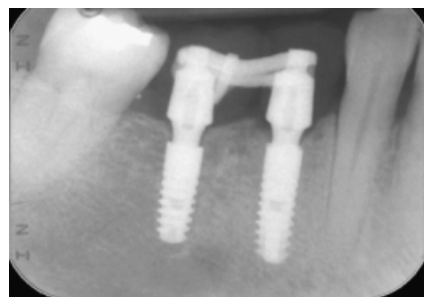

Fig. 2. Test case: periapical radiograph taken immediately after surgery.

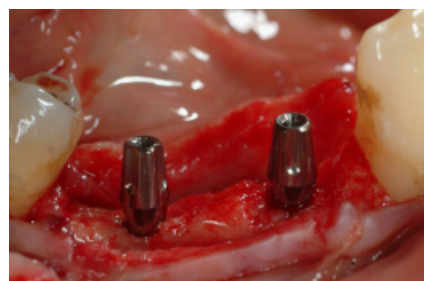


Fig. 3. Test case: final abutments in position immediately after surgery.

- T1: fitting of the final restoration – 6 months after surgery;
- T2: final restoration follow-up – 1 year after surgery;
- T3: final restoration follow-up – 2 years after surgery;
- T4: final restoration follow-up – 3 years after surgery.

Intraobserver and interobserver reliability checks were carried out for the radiographic measurements in order to evaluate the method error. Fifty digitized radiographs were randomly selected in both groups and measurements were performed again by the same operator (D. N.) and by a dental school student 1 month after the first assessment.

**Statistical analysis**

Statistically significant difference in the vertical and the horizontal bone levels was assessed at each follow-up between the test and the control group using the non-parametric Wilcoxon's *t*-test with a 95% confidence interval ( $P < 0.05$ ). The mesial and the distal measurements on each implant were averaged and used as a statistical element.

The intraobserver reliability was assessed using the Pearson's correlation coefficient.

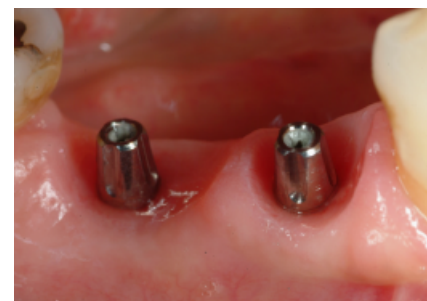

Fig. 6. Test case: healing of the soft tissue 6 months after surgery, lateral view.

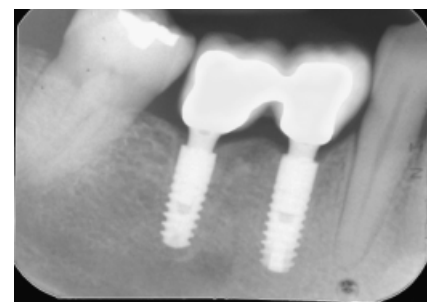


Fig. 7. Test case: periapical radiograph taken 3 years after surgery.

The interobserver reliability was assessed using the Intraclass correlation coefficient (ICC) (Everitt 1989).

Results

A total of 48 implants that fulfilled the inclusion criteria were placed in the period between February 2006 and April 2007. The mean age of the patients at the time of surgery was 49.3 years (SD = 8.3; *n* = 24). 30 (62.5%) and 18 (37.5%) restorations were, respectively, placed in an equal number of female and male patients. All the restorations were placed in between natural teeth and had at least one molar distal to them. Average insertion torque and ISQ values are listed in Table 1. At the 36-month follow-up, bone was found coronally to the implant platform in the area drilled during surgery; respectively, 0.608 mm (SD = 0.350) in the test group and 0.529 mm (SD = 0.332) the control group. At the same follow-up, 0.225 mm (SD = 0.175) of bone was found growing over the rough implant shoulder in the test group, and 0.104 mm (SD = 0.196) the control group. No statistically significant difference was evidenced between the two groups regarding the measurement of vertical bone healing. A small but significant horizontal bone loss was evidenced in the hard tissue portion over the implant platform in the period of time between the 6-month and 1-year follow-up in the control group (Table 2). The radiographic data are summarized in Tables 3 and 4. Both implants in one patient and one implant in two other cases failed to achieve the minimal insertion torque value requested for the inclusion in this study. All three cases were then dropped from the study and treated with a one-stage approach. The value of the Pearson's correlation coefficient used to assess the intraobserver reliability was 0.927. The value of the intraclass correlation coefficient used to assess the interobserver reliability was 0.804.

One patient of the control group reported pain and moderate edema associated with an external ecchymosis immediately after surgery. Pain was controlled with 1000 mg of paracetamol (Tachipirina 1000, Angelini Farmaceutici, Roma, Italy) twice daily for 5 days, and ceased 1 week after surgery. All external signs had gone 10 days after implant placement without any additional treatment.

One of the test group reported substantial discomfort associated with early mucositis immediately after the delivery of the final restoration. The restoration was then removed, carefully modified in order to reduce lateral pressure on the soft tissue and immediately screw retained.

Discussion

This study achieved a 100% implant and prosthetic success rate at the 36-month follow-up

Table 1. Average insertion torque and ISQ values

	OA/OT group (test, <i>n</i> = 24)	Standard protocol (control, <i>n</i> = 24)
Torque (N cm)	47.5 (SD 12.3)	46.8 (SD 14.9)
ISQ (T0, surgery)	70.1 (SD 6.2)	71.6 (SD 6.1)
ISQ (T1, 6 months)	76.2 (SD 6.8)	77.5 (SD 8.1)
ISQ, implant stability quotient.		

Table 2. Statistical difference in vertical and horizontal bone levels

Follow-up	One abutment/one time group	Standard protocol	<i>P</i>
Vertical height of the bone peak			
T1 – 6 months	0.679	0.683	0.98
T2 – 1 year	0.641	0.570	0.31
T3 – 2 years	0.616	0.541	0.28
T4 – 3 years	0.608	0.529	0.30
Horizontal grow of the bone over the implant platform			
T1 – 6 months	0.275	0.279	0.96
T2 – 1 year	0.254	0.120	0.009
T3 – 2 years	0.245	0.116	0.024
T4 – 3 years	0.225	0.104	0.042

Table 3. Vertical bone measurements

Follow-up	Mean bone level	SD	Median	Loss since previous follow-up
One abutment/one time group (test, <i>n</i> = 24)				
T1 – 6 months	0.679	0.184	0.65	NA
T2 – 1 year	0.641	0.244	0.65	0.037
T3 – 2 years	0.616	0.315	0.6	0.025
T4 – 3 years	0.608	0.350	0.6	0.008
Standard protocol (control, <i>n</i> = 24)				
T1 – 6 months	0.683	0.227	0.7	NA
T2 – 1 year	0.570	0.286	0.6	0.112
T3 – 2 years	0.541	0.307	0.6	0.029
T4 – 3 years	0.529	0.332	0.6	0.012
NA, not applicable				

Table 4. Horizontal bone measurements

Follow-up	Mean bone level	SD	Median	Loss since previous follow-up
One abutment/one time group (test, <i>n</i> = 24)				
T1 – 6 months	0.275	0.153	0.3	NA
T2 – 1 year	0.254	0.155	0.3	0.020
T3 – 2 years	0.245	0.164	0.3	0.008
T4 – 3 years	0.225	0.175	0.3	0.020
Standard protocol (control, <i>n</i> = 24)				
T1 – 6 months	0.279	0.141	0.3	NA
T2 – 1 year	0.120	0.186	0.15	0.158
T3 – 2 years	0.116	0.185	0.1	0.004
T4 – 3 years	0.104	0.196	0.1	0.012
NA, not applicable.				

examination for both the study and the control group. There was no significant statistical difference between the two procedures involved in our study in terms of measured vertical bone healing. A smaller resorption was assessed in the "one abutment at one time" (study) group 1 year after surgery; these data were, however, not statistically significant. Four months after subcrestal placement of tapered implants (OsseoSpeed®, Astra Tech Dental, Molndal, Sweden), Welander et al. (2009) stated in an animal study that control abutments with a smooth surface were

unable to achieve new bone formation on their surface. In our study, the radiological evidence of this contact was present in only one (4.17%) implant of the test group.

The results of the reliability checks demonstrated not only a good intraobserver reproducibility for the measurement method used in our study, but also its tendency to be influenced in its precision by clinical experience of the assessor.

In the control cases of our study, which were treated in accordance with the guidelines of the manufacturer, a small but significant horizontal

bone loss was observed to be present in the hard tissue portion over the implant platform between the 6-month and 1-year follow-up. This loss was not recovered in the following follow-up examinations. The histomorphometrical evaluation of the peri-implant soft tissues around immediately loaded tapered implants in the human mandible has been extensively examined in a recently published study (Romanos et al. 2010). The authors of this paper suggested that the non-removal of the abutment in the applied prosthetic protocol was certainly an important factor in achieving the good bone healing results reported in their paper. The results of our study seem to confirm that if the implant–abutment unit is not altered or modified over time, the favorable healing of the hard tissue obtained in the first months after surgery can be safeguarded for as long as 3 years after implant placement. The final outcome of the implant treatment is not compromised by the removal of the immediate abutment, as evidenced by the same percentage of success achieved by the two groups of our study. The adoption of the “one abutment at one time” protocol grants a reduction of the clinical procedures and an improvement to an already well-established and proven approach. This study

focused only on the effects of the abutment disconnection on the hard tissue. The patient biotype and the width of the mucosa were not examined as a clear histological analysis of the soft tissue response to our test procedures was not possible.

As already suggested by the authors (Degidi et al. 2010), it is not possible to clearly compare the results of mean marginal bone loss of butt-joint connection implants with machined collar and those for tapered implants with a rough collar due to the very different nature of the surgical protocols involved. The subcrestal placement of tapered implants requires different quantities of bone to be drilled during surgery. The quantity of this bone recovered in the healing process and its stability in the long-term follow-up will determine the success of this surgical treatment. The horizontal measurement of bone overgrowing the implant platform is to be recommended, in order to better evaluate the outcome of a treatment involving subcrestally placed tapered implants and to better compare the results obtained with different implant systems using this surgical approach. However, as observed by Donovan et al. (2010) only mesial and distal bone levels were assessed due to the intrinsic limita-

tion of periapical X-rays, whereas no assessment was made of the facial or lingual sites. The future use of CBCT technology will without doubt assist in the effort to clearly determine hard tissue behavior in those areas.

## Conclusions

The non-removal of abutments placed at the time of the surgery results in a statistically significant reduction of the horizontal bone remodeling around the immediately restored, subcrestally placed tapered implant in cases of partial posterior mandibular edentulism. Horizontal measurement of the bone growing over the implant platform is to be recommended in studies involving subcrestally placed tapered implants.

**Acknowledgements:** The authors would like to thank Mr Gianluca Sighinolfi, dental technician in private practice, Bologna, Italy, for his invaluable technical support. The authors have no commercial or financial relationship that may pose a conflict of interest or potential conflict of interest.

## References

- Abrahamsson, I., Berglundh, T., Sekino, S. & Lindhe, J. (2003) Tissue reactions to abutment shift: an experimental study in dogs. *Clinical Implant Dentistry & Related Research* **5**: 82–88.
- Albrektsson, T., Zarb, G., Worthington, P. & Eriksson, R.A. (1986) The long-term efficacy of currently used dental implants: a review and proposed criteria of success. *The International Journal of Oral & Maxillofacial Implants* **1**: 11–25.
- Buser, D., Dula, K., Belser, U., Hirt, H.P. & Berthold, H. (1993) Localized ridge augmentation using guided bone regeneration. 1. Surgical procedure in the maxilla. *International Journal of Periodontics and Restorative Dentistry* **13**: 29–45.
- Degidi, M., Iezzi, G., Scarano, A. & Piattelli, A. (2008) Immediately loaded titanium implant with a tissue-stabilizing/maintaining design (“beyond platform switch”) retrieved from man after 4 weeks: a histological and histomorphometrical evaluation. A case report. *Clinical Oral Implants Research* **19**: 276–282.
- Degidi, M., Nardi, D. & Piattelli, A. (2010) Prospective study with a 2-year follow-up on immediate implant loading in the edentulous mandible with a definitive restoration using intra-oral welding. *Clinical Oral Implants Research* **21**: 379–385.
- Donovan, R., Fetner, A., Koutouzis, T. & Lundgren, T. (2010) Crestal bone changes around implants with reduced abutment diameter placed non-submerged and at subcrestal positions: a 1-year radiographic evaluation. *Journal of Periodontology* **81**: 428–434.
- Everitt, B.S. (1989) Statistical methods for medical investigations. In: Edward, A., ed. *Statistical Methods for Medical Investigations*. 1st edition, 25–27. New York: Oxford University Press.
- Hämmerle, C.H., Brägger, U., Bürgin, W. & Lang, N.P. (1996) The effect of subcrestal placement of the polished surface of ITI implants on marginal soft and hard tissues. *Clinical Oral Implants Research* **7**: 111–119.
- Hartman, G.A. & Cochran, D.L. (2004) Initial implant position determines the magnitude of crestal bone remodeling. *Journal of Periodontology* **75**: 572–577.
- Jaffin, R.A., Kolesar, M., Kumar, A., Ishikawa, S. & Fiorellini, J. (2007) The radiographic bone loss pattern adjacent to immediately placed, immediately loaded implants. *The International Journal of Oral & Maxillofacial Implants* **22**: 187–194.
- Lazzara, R.J. & Porter, S.S. (2006) Platform switching: a new concept in implant dentistry for controlling postrestorative crestal bone levels. *International Journal of Periodontics and Restorative Dentistry* **26**: 9–17.
- Quirynen, M., Bollen, C.M., Eyssen, H. & van Steenberghe, D. (1994) Microbial penetration along the implant components of the Branemark system: an in vitro study. *Clinical Oral Implants Research* **5**: 239–244.
- Quirynen, M. & van Steenberghe, D. (1993) Bacterial colonization of the internal part of two-stage implants. An in vivo study. *Clinical Oral Implants Research* **4**: 158–161.
- Romanos, G., Toh, C.G., Siar, C.H., Swaminathan, D., Ong, A.H., Donath, K., Yaacob, H. & Nentwig, G.H. (2001) Periimplant bone reactions to immediately loaded implants. An experimental study in monkeys. *Journal of Periodontology* **72**: 506–511.
- Romanos, G.E., Traini, T., Johansson, C.B. & Piattelli, A. (2010) Biologic width and morphologic characteristics of soft tissues around immediately loaded implants: studies performed on human autopsy specimens. *Journal of Periodontology* **81**: 70–78.
- Roos-Jansaker, A.M., Lindahl, C., Renvert, H. & Renvert, S. (2006) Nine to fourteen-year follow-up of implant treatment. Part I: implant loss and associations to various factors. *Journal of Clinical Periodontology* **33**: 283–289.
- Stein, A.E., McGlmpy, E.A., Johnston, W.M. & Larsen, P.E. (2009) Effects of implant design and surface roughness on crestal bone and soft tissue levels in the esthetic zone. *The International Journal of Oral & Maxillofacial Implants* **24**: 910–919.
- Welander, M., Abrahamsson, I. & Berglundh, T. (2009) Subcrestal placement of two-part implants. *Clinical Oral Implants Research* **20**: 226–231.
- Weng, D., Nagata, M.J., Bell, M., Bosco, A.F., de Melo, L.G. & Richter, E.J. (2008) Influence of microgap location and configuration on the periimplant bone morphology in submerged implants. An experimental study in dogs. *Clinical Oral Implants Research* **19**: 1141–1147.